

# COMPARISON OF QUANTITATIVE EVALUATION AND CONVENTIONAL SCAR SCALE ANALYSIS FOR PEDIATRIC PATHOLOGICAL SCARS

Jin-Ye Guan <sup>1,†</sup>, Xing Zou <sup>1,†</sup>, Jun-Wen Ge <sup>1</sup>, Rui-Cheng Tian <sup>1</sup>, Wei Liu <sup>2</sup>,  
Mei-Yun Li <sup>1,\*</sup> and Dan Deng <sup>1,\*</sup>

Jin-Ye Guan <sup>1,†</sup>, Xing Zou <sup>1,†</sup>,  
Jun-Wen Ge <sup>1</sup>, Rui-Cheng Tian <sup>1</sup>,  
Wei Liu <sup>2</sup>, Mei-Yun Li <sup>1,\*</sup> and Dan  
Deng <sup>1,\*</sup>

<sup>1</sup>Department of Dermatology, Shanghai Children's Medical Center, Shanghai Jiao Tong University School of Medicine, Shanghai 200127, China.

<sup>2</sup>Shanghai Key Laboratory of Tissue Engineering, Department of Plastic and Reconstructive Surgery, Shanghai Ninth People's Hospital, Shanghai Jiao Tong University School of Medicine, Shanghai 200011, China.

## Running Title

Comparison of Quantitative Evaluation and Conventional Scar Scale Analysis for Pediatric Pathological Scars

Word Count - 448 words

## BACKGROUND

The incidence of pediatric pathological scars (PPS) has been gradually increasing due to various causes, highlighting the need for accurate scar assessment to monitor disease progression and therapeutic efficacy. Vancouver Scar Scale (VSS) and other scar evaluation systems are relatively subjective evaluation methods that rely on physicians' or patients' own judgment. By contrast, when comparing different scar scale evaluation methods, a three-dimensional (3D) camera and dermoscopy may provide relatively objective measurable parameters to avoid possible subjective bias created by the observers. This study aimed to compare the utility of traditional VSS evaluation with that of 3D cameras and dermoscopy in PPS evaluation.

## METHODS

A total of 35 pediatric patients (aged 0–18 years) with PPS were involved, and their scars were assessed via the VSS, dermoscopy, and the Antera 3D<sup>®</sup> system. In addition, a subset of 18 patients (36 scar regions) was also evaluated for therapeutic efficacy after 3–6 months of treatment. Briefly, VSS scores were blindly evaluated by two independent dermatologists under standardized conditions. Quantitative assessment was also performed using dermoscopy and the Antera 3D<sup>®</sup> system. The former quantified chromatic parameters (pigmentation: L\*, vascularity: a\*, green value); the latter captured multispectral 3D images to analyze volume, pigmentation, and erythema. Data are presented as means ± standard deviation and analyzed using paired-sample t tests (one-tailed), the Wilcoxon signed-rank test, and standardized response means (SRMs) to assess therapeutic sensitivity, while baseline variability was evaluated using the standard deviation and coefficient of variation (CV).

## RESULTS

The results showed that Antera 3D<sup>®</sup> detected significant reductions in pigmentation ( $p < 0.01$ , SRM = -0.46), vascularity ( $p < 0.001$ , SRM = -0.59), and volume ( $p < 0.0001$ , SRM = -0.83), while dermoscopy indicated similar moderate improvements in vascularity (Green value:  $p < 0.001$ , SRM = 0.57; a\*:  $p < 0.0001$ , SRM = -0.68) and pigmentation (L\*:  $p < 0.0001$ , SRM = 0.48) after treatments. VSS showed significant gains in pliability ( $p < 0.0001$ , SRM = -1.13), height ( $p < 0.01$ , SRM = -0.54), and overall impression ( $p < 0.0001$ , SRM = -0.86), but minimal changes in pigmentation ( $p > 0.05$ , SRM = 0) or vascularity ( $p > 0.05$ , SRM = -0.21). At baseline, Antera 3D<sup>®</sup> showed the greatest variability in pigmentation (CV 43.41%) and volume (CV 91.21%), followed by VSS in vascularity (CV 52.95%), pliability (CV 34.05%), and overall impression (CV 31.76%). Dermoscopy presented the lowest variability, indicating limited discriminative power.

### CONCLUSION

In conclusion, Antera 3D® offers an objective, sensitive, and spatially precise approach for PPS assessment and may provide additional quantitative information for evaluating subtle and early changes alongside traditional scar assessment scales. Its integration into clinical practice will enhance treatment monitoring and support more accurate timing of therapeutic interventions.




Figure 1. Representative workflow of scar selection and imaging analysis




Figure 2. Estimation plots of paired t tests for pre-post changes in scar parameters assessed by VSS, dermoscopy, and Antera 3D® for 36 scar scars from 12 patients

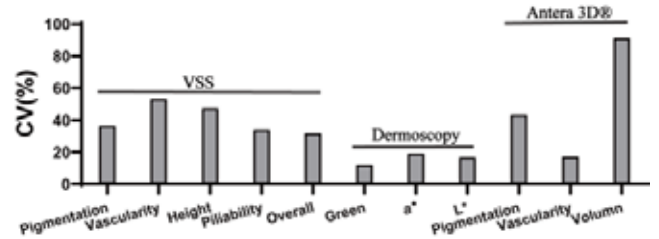


Figure 3. Baseline coefficient of variation (CV) values of scar parameters measured by VSS, dermoscopy, and Antera 3D®