

**KRF Clinical Practice Guidelines in Keloid Disorder (KRF Guidelines®)**

# Cryotherapy

Version 1.2018 — November 30, 2018

**Author: Michael H. Tirgan, MD**

[KeloidResearchFoundation.org](http://KeloidResearchFoundation.org)

**Michael H. Tirgan, MD (Chair)**  
Keloid Research Foundation  
New York, USA

We, the undersigned, fully endorse and support the recommendations and content of this Guideline and have adapted this into our own medical practices.

**Raul Caceres, MD**  
Plastic Surgery  
New York, USA

**Patricia Danielsen, MD, PhD**  
Department of Dermatology  
University Hospital of Copenhagen  
Copenhagen  
Denmark

**Reza Ghohestani, MD, PhD**  
Texas Institute of Dermatology  
San Antonio, Texas  
USA

**Prof. Dr. Jürg Hafner**  
Division of In-Hospital Dermatology &  
Surgical Dermatology  
Department of Dermatology  
University Hospital of Zurich  
Zurich, CH-8091  
Switzerland

**Tamara Maravic-Gidakovic, MD**  
Dermatology and Venereology  
Dermanova  
Belgrade  
Serbia

**Tae Hwan Park, MD, PhD**  
Department of Plastic and  
Reconstructive Surgery  
CHA University College of Medicine  
59 Yatap-ro, Bundang-gu, Seongnam,  
Gyeonggi 13496,  
Korea

The KRF Guidelines® are statements of evidence and consensus of the authors regarding their views of currently accepted approaches to treatment. Any clinician seeking to apply or consult the KRF® Guidelines is expected to use independent medical judgement in the context of individual clinical circumstances to determine any patient's care or treatment. The Keloid Research Foundation® (KRF®) makes no representations or warranties of any kind regarding their content, use or application and disclaims any responsibility for their application or use in any way. The KRF® Guidelines are copyrighted by Keloid Research Foundation. All rights reserved. The KRF Guidelines and the illustrations herein may not be reproduced in any form without the express written permission of KRF®. ©2018.

## CONTACT CRYOTHERAPY

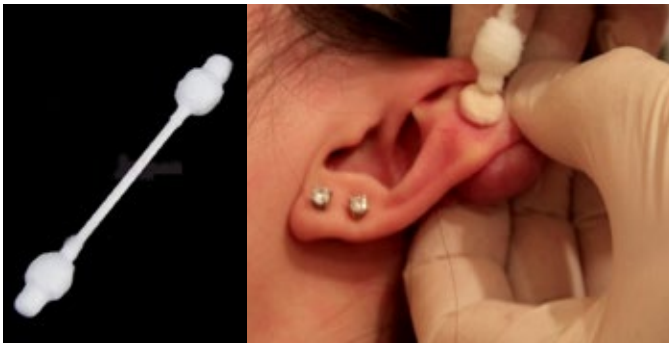
Usage of cryotherapy in treatment of keloids dates back to 1950 [1]. There are numerous references about efficacy of cryotherapy in treatment of keloids [2,3]. Focus of this Guideline, however, is not to review this literature. The aim of this document is to discuss the method for proper application of this treatment modality as well as review of the clinical outcomes. Terms cryotherapy in this document and in the rest of the KRF Guidelines refers to contact cryotherapy. KRF does not endorse other methods of applying cryotherapy such as spray gun, intra-lesional.

## PROPER APPLICATION

Like any other medical procedure, contact cryotherapy should be delivered properly in order to achieve optimal results. Materials that are needed to apply cryotherapy are:

1. Liquid nitrogen
2. Properly sized cotton swab

For keloids that are few millimeters in diameter, the readily available cotton swabs (Figure 1) can be used.

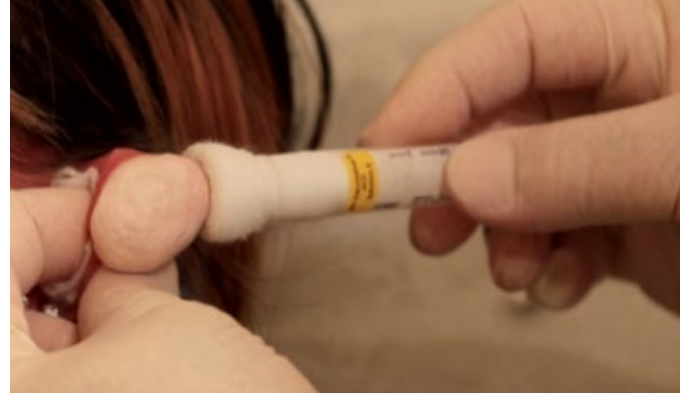

**Figure 1.** Commercially available cotton swab being used to apply cryotherapy to a small ear keloid.

For keloids that are larger than one centimeter, the author custom makes his own swabs by rolling a non-woven medical gauze and inserting one end of the rolled gauze inside a 10 ml test tube. The exposed end of the gauze is then cut with scissors to achieve a flat tip surface (Figure 2).

Liquid nitrogen is brought to patient's bedside in a styrofoam cup. The cup is placed at a level that is lower than the patient to avoid injury to the patient in case of accidental spillage.

Once all preparations are made and the keloid is ready for cryotherapy, the swab is dipped in liquid nitrogen and brought in contact with the keloid. The swab is gently pushed against the keloid and is held in place until the lesion starts to freeze. The frozen keloid tissue will appear white in color (Figure 2).



**Figure 2.** Custom made large cotton swab being used during the application of cryotherapy to a large ear keloid. The frozen keloid appears white.

Since liquid nitrogen evaporates quickly, the swab needs to be dipped in the cup frequently and re-applied to the keloid. This process is repeated several times until the whole keloid tissue is frozen to the normal skin level. Figures 2-4 depict the appearance of properly frozen ear keloids.

The author advises against spray method as well as intra-lesional cryotherapy.

## PAIN CONTROL

Cryotherapy is a painful procedure. Pain starts immediately after the application of liquid nitrogen and can last for 24-48 hours. The smaller the keloid is, the less pain there will be during and after the procedure. Application of cryotherapy to large, semi-massive and massive keloids can be quite painful, and without taking proper measures, the procedure cannot be completed as planned. Pain control is the most important factor in achieving success with cryotherapy. Poor pain control will result in lack of compliance and interrupted treatment cycles.

### Pain Control for Small Keloids

Cryotherapy can be applied to most small keloids - like the one depicted in Figure 3 - without local anesthesia. Patients need to be advised that there will be some degree of pain and discomfort during and after the procedure. Most patients do well without any pain medications. If need be, the author prescribes ibuprofen or acetaminophen for pain relief in this setting.

While applying cryotherapy, the physician shall constantly inquire about the pain and assess patient's tolerance on an ongoing basis. Most patients with small keloids do very well and can tolerate cryotherapy by simply talking to them during the procedure. There will, however, be a small minority who will not be able to tolerate the procedure. Local anesthetics are indicated for all these patients. Also, when treating children and teenagers, it is best to use a local anesthetic prior to initiation of cryotherapy.

### Pain Control for Large Keloids

Pain control is the mainstay of successful treatment of patients with large ear keloids. Although standard local anesthesia will allow for the procedure to be completed, recurrent pain after the anesthetic effect fades needs to be addressed.

Recently, liposomal bupivacaine (Exparel®) has become commercially available in Unites States and is the author's drug of choice for all patients who need local anesthetic [4]. This product induces a durable local anesthesia, perhaps up to 72 hours. The great majority of patients who are treated with this product experience very little or no pain at all. This product has virtually eliminated the need for potent oral pain medication in the author's practice.

For earlobe keloids, the product is injected inside the earlobe but above the keloid mass, i.e. in the path of transmission of the pain signals. For ear keloids that are on the helix of the ear, the product is injected in the base of the keloid and all around it.

After the procedure is completed, patients should be monitored for 1-2 hours for breakthrough pain. Breakthrough pain is treated with injection of more

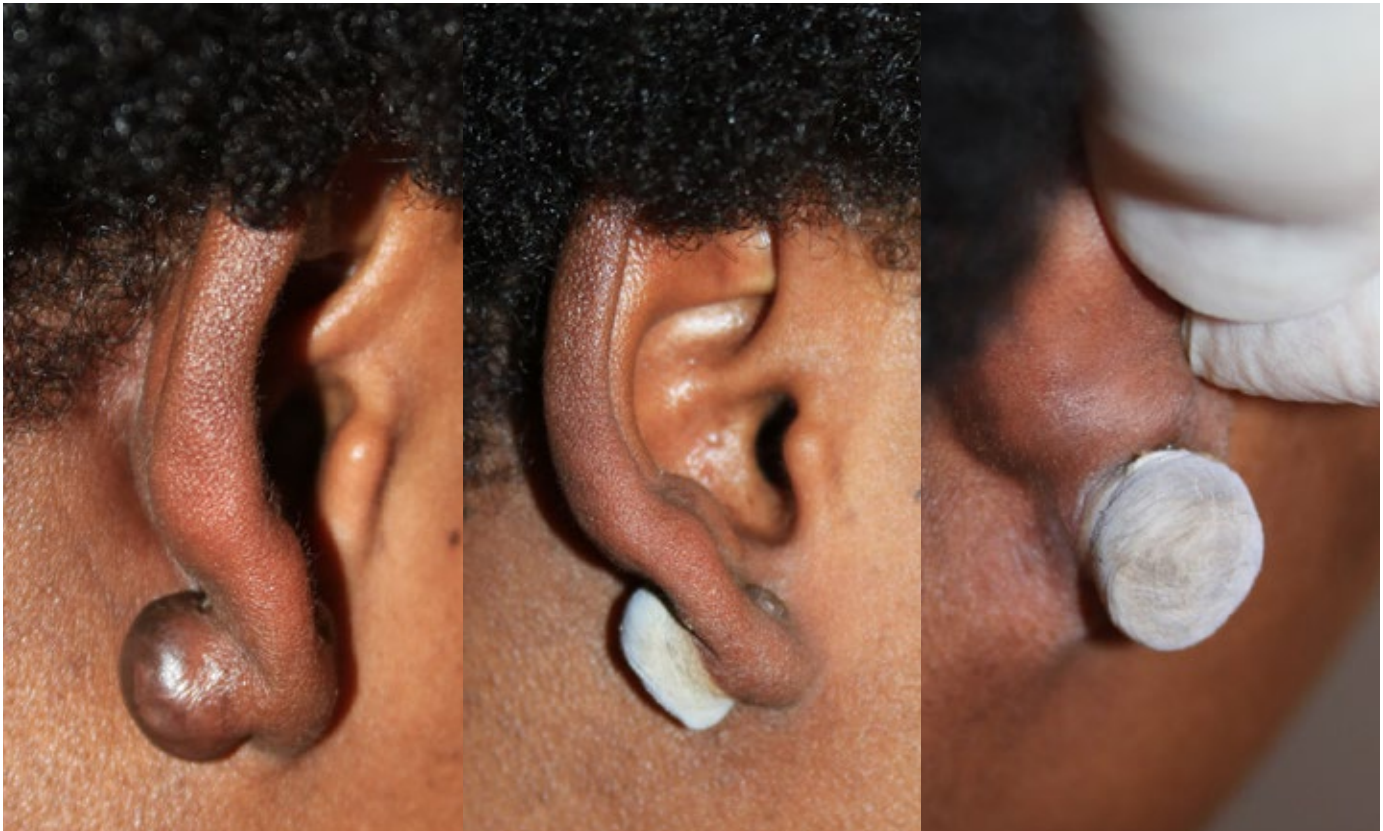liposomal bupivacaine in the area where the patient is experiencing the pain.

Pain control is the most critical element of treatment during and after the application of cryotherapy. Inadequate pain control will result in lack of compliance and a poor treatment outcome. Where liposomal or other long acting local anesthetics are not available, all patients should be educated about the treatment-induced pain and also be prescribed proper oral pain medication.

### NECROSIS AND RECOVERY CYCLE

Application of cryotherapy to the living tissue induces tissue injury which ultimately leads to tissue necrosis. Figures 2-4 depict the appearance of the frozen ear keloids immediately after the application of cryotherapy. Educating patients about this process, as well as proper aftercare that is needed to manage the treated keloid, is extremely important.

It is common sense that smaller keloids will freeze faster and will require fewer applications of liquid nitrogen. Larger keloids will obviously need a greater number of applications of liquid nitrogen in order to be properly and adequately frozen.

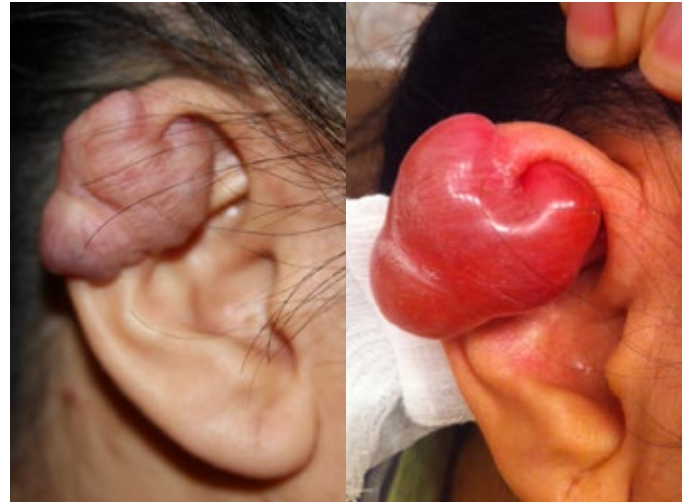

**Figure 3.** Earlobe keloid, before (left) and after application of cryotherapy (middle and right). The frozen keloid tissue appears white in color. In most cases, this size keloid can be treated without local anesthesia.

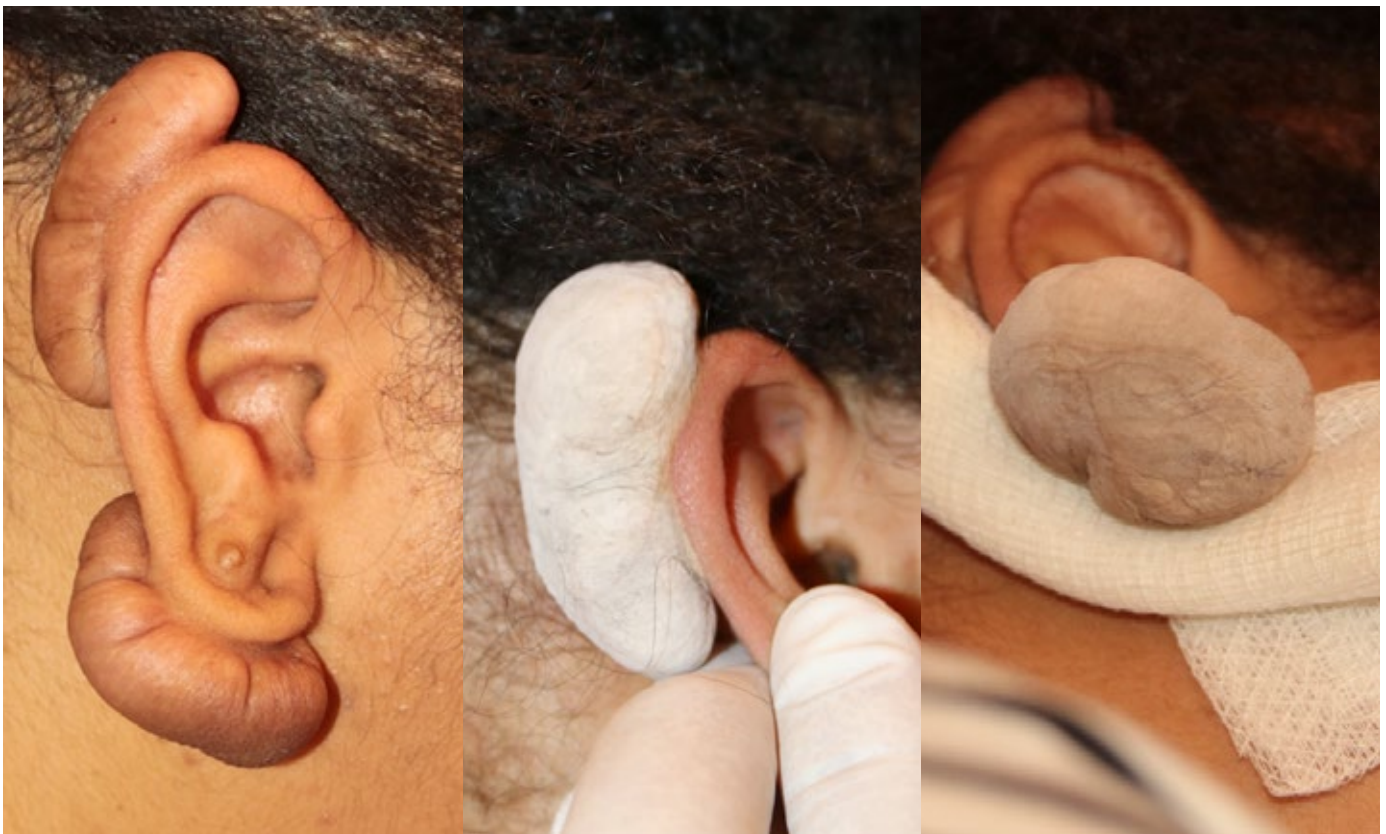Application of cryotherapy to very large and massive keloids is rather complex and requires proper planning, proper pain management and proper patient education. In treating massive keloids, it is best not to treat the whole keloid in one session, but to divide the procedure into 3-4 separate sessions, each spaced 3-4 weeks apart. This approach will allow for easier aftercare.

### THE AFTERMATH

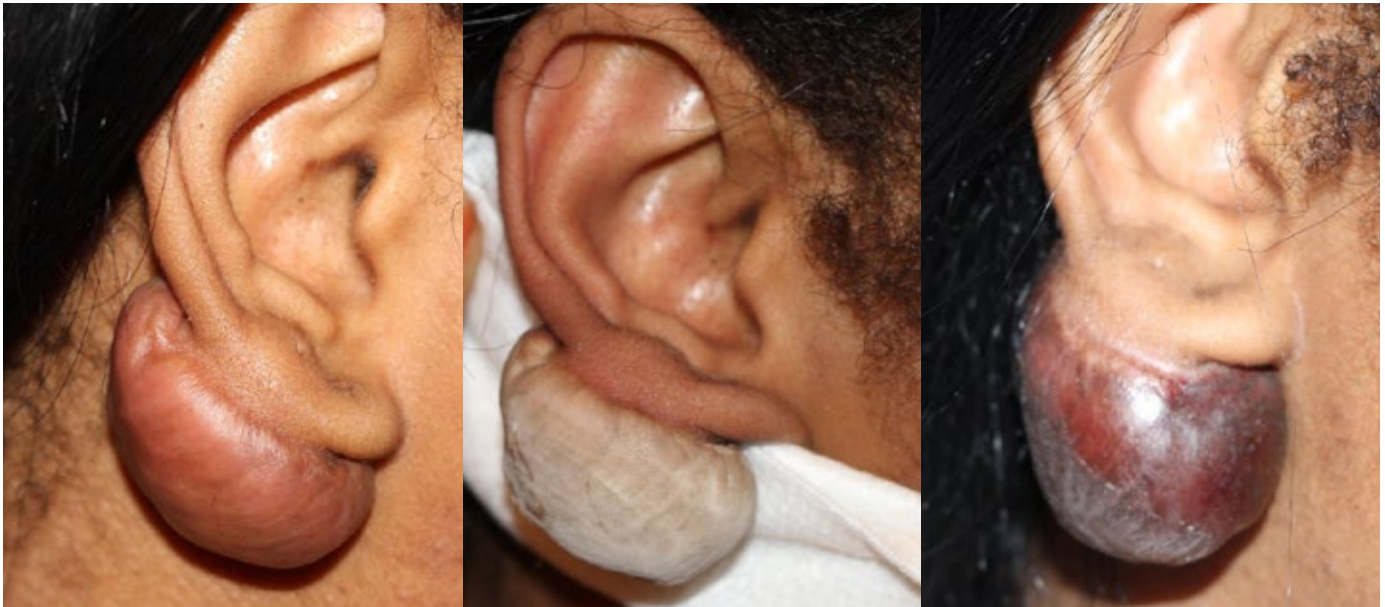Within the first few hours of application of cryotherapy, the treated keloid tissue becomes edematous and swollen (Figure 5). The treated area should be bandaged. Patient education about the aftercare should take place prior to initiation of therapy. Patients should be instructed to remove and replace the bandage at least once a day, or as soon as they notice staining of the gauze. It is important to keep the bandage as clean and as dry as possible at all times.



**Figure 5.** Complex ear keloid before (left) and one hour after application of cryotherapy (right). The frozen keloid thaws within several minutes after cryotherapy. Soon after the treated keloid becomes edematous and forms a blister. Notice that the tissue around the blister appears totally normal.

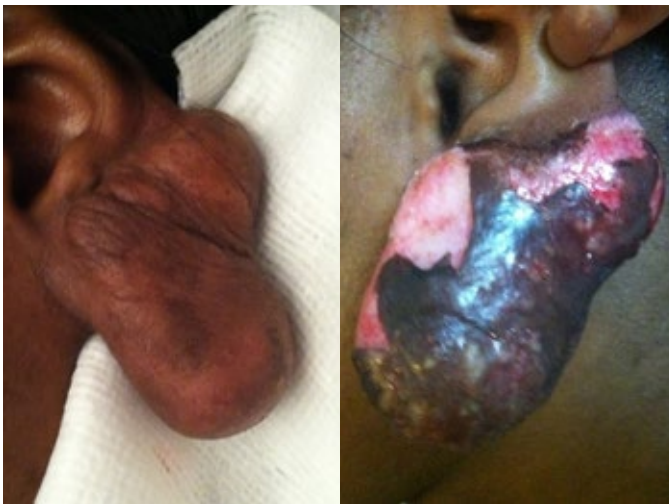

**Figure 4.** Semi-massive ear keloids before (left) and immediately after application of cryotherapy (middle and right). Treating a keloid this size should best be done under local anesthesia using liposomal bupivacaine or other similar long-acting local anesthetics.



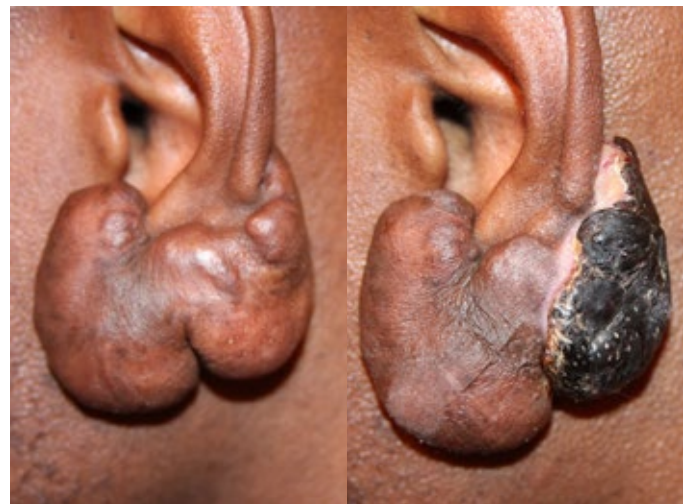**Figure 6.** Right ear keloid before (left), immediately after (center) and five days after the application of cryotherapy (right). Notice that the keloid is undergoing necrosis and the overlying skin is starting to form a thin dark layer.

The cryotherapy-induced blister behaves very similarly to a burn-induced blister and will sooner or later disintegrate. The exudative fluid that leaks from the blister is serous or serosanguinous. The oozing and leakage of the exudative fluid continues for about a week, at which point the keloid tissue starts to contract to its pre-treatment size. A dark color scab starts forming on the surface of the treated keloid (Figure 6). The scab gradually thickens (Figures 7-8) yet remains in place for several weeks before it fully separates from the underlying tissue.



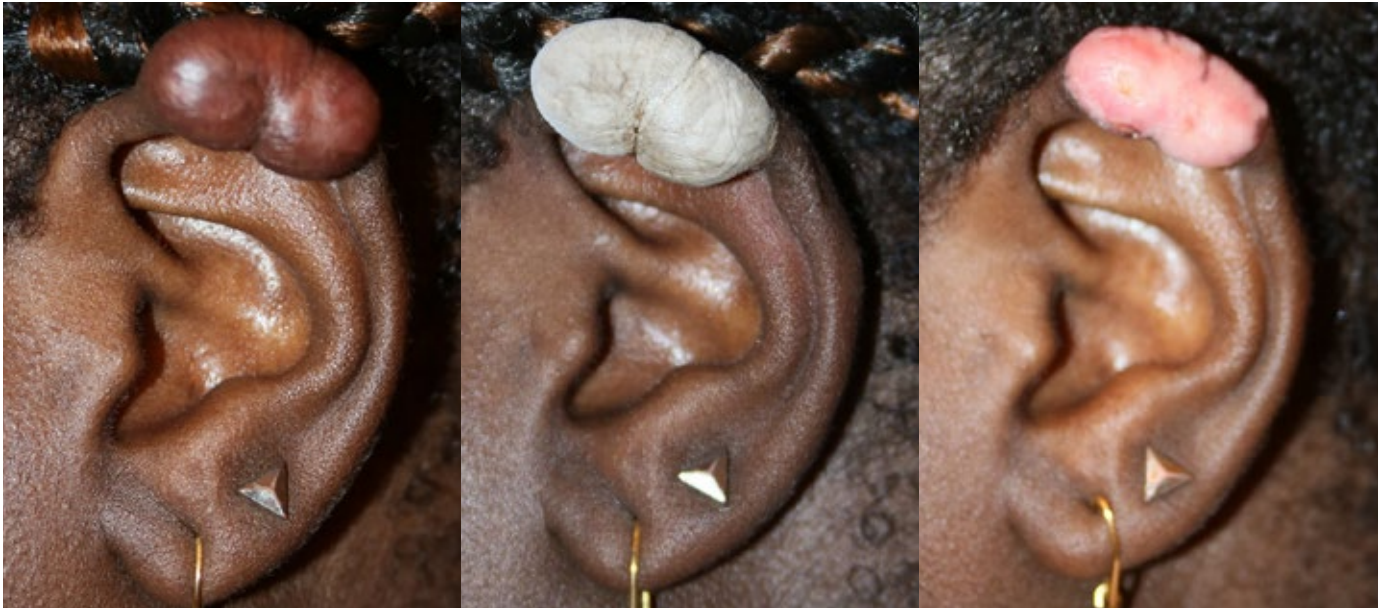**Figure 7.** Complex ear keloid before (left) and 10 days after application of cryotherapy (right). Notice that the keloid tissue is undergoing necrosis and the disintegrated skin is starting to transform into a dried scab.

The duration of the necrosis and recovery cycle depends on the size of the treated keloid and varies from patient to patient. Keloids that measure less than one centimeter in diameter will go through this cycle in about 3-4 weeks. The cycles take longer for larger keloids, lasting about 8-12 weeks for very large lesions.



**Figure 8.** Complex ear keloid before (left) and 24 days after application of cryotherapy (right). Notice the formation of the thick black scab over the segment that was treated with cryotherapy.

The dehydrated thick scab will eventually fall off. The newly formed skin is pink in color and devoid of pigment (Figure 9). In the author's experience, most keloids undergo approximately 30–60% reduction in mass after recovery from the first cryotherapy. Cryotherapy should be repeated once the necrosis and recovery cycle is complete (Figure 9).



**Figure 9.** Ear keloid before (left) immediately after (center) and 41 days after application of cryotherapy (right). Note that the scab has already fallen off and there is lack of pigment at the treatment site. Also note the reduction in the mass of keloid after recovery from the first treatment. The necrosis and recovery cycle is now complete, and the patient is ready to receive the next course of cryotherapy.

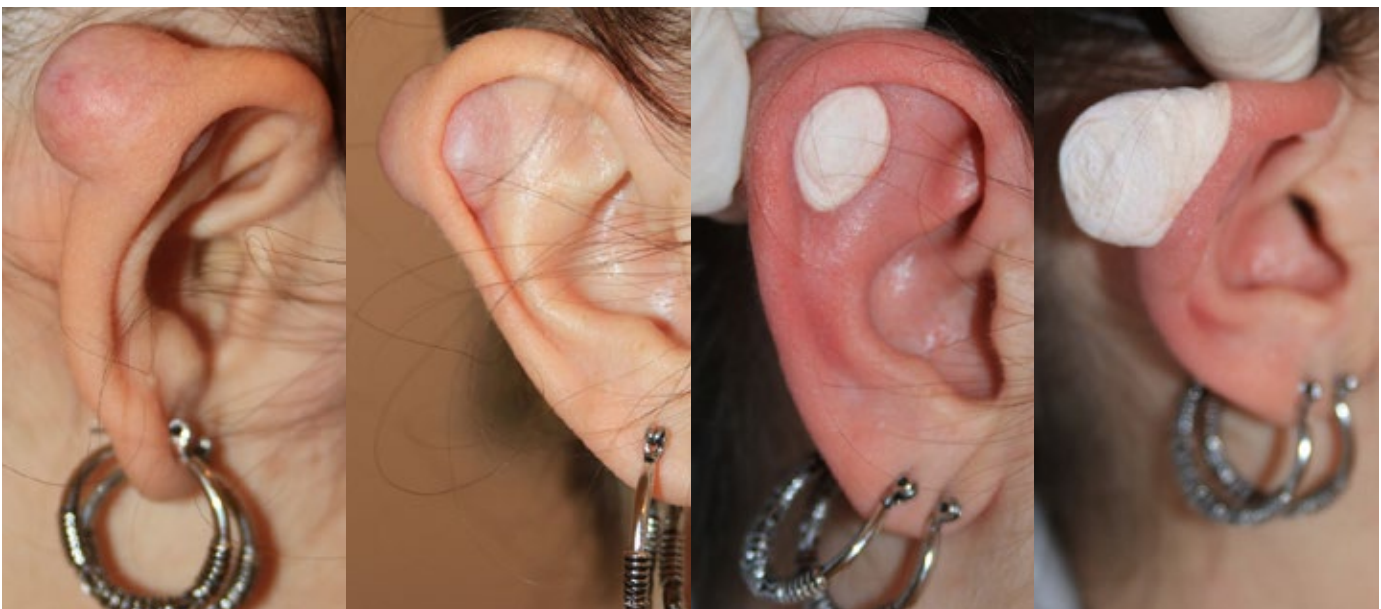### ACCELERATED CRYOTHERAPY

The author prefers to wait and allow for full recovery and epithelization of the underlying tissue before starting the next cycle of cryotherapy. However, for the patients whose schedules do not allow for a lengthy course of treatment, the author repeats cryotherapy once the edema and oozing of the treated keloid has subsided. In these situations, cryotherapy is applied once every 2-4 weeks, depending on the patients' schedules, regardless of the presence of the scab. Figures 10-11 depict one such case.

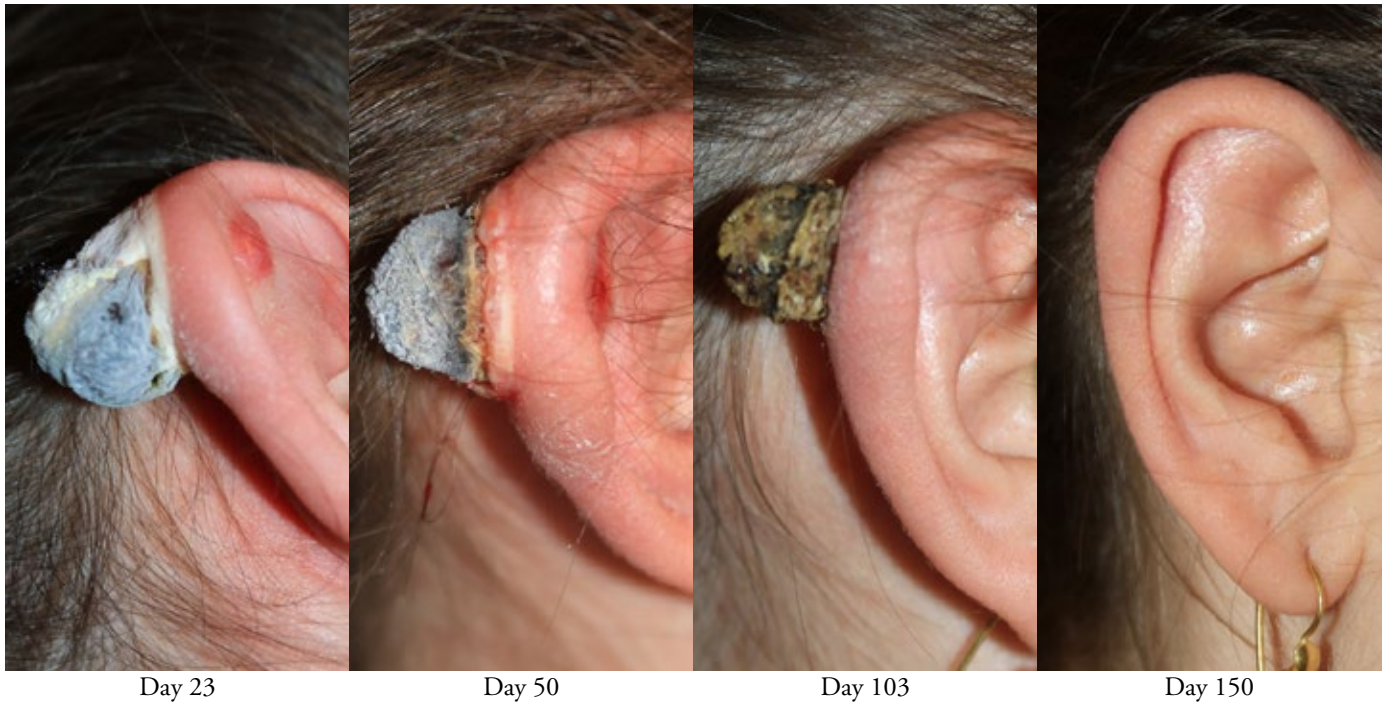### EXPECTED OUTCOME

#### Bulky Keloids

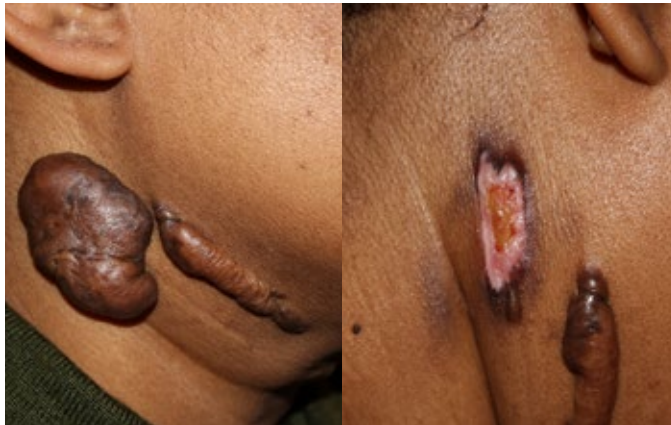Cryotherapy is an effective and safe method for treating bulky keloids. When performed correctly, significant debulking can be achieved, even with one cycle of cryotherapy (Figure 11). It is important to note that cryotherapy may not be a curative treatment for keloid disorder, but it is a safe method to reduce the mass of keloids and provide symptom relief and comfort to the patients.



**Figure 10.** Ear keloid before and immediately after application of cryotherapy to both anterior and posterior segments of the keloid (Day 0).



**Figure 11.** Ear keloid immediately after application of the 2<sup>nd</sup> cryotherapy on Day 23 with the scab in place; after 3<sup>rd</sup> cryotherapy on Day 50 still with the scab in place; Day 103 after the first treatment still with the original scab in place. The furthest right image depicts the ear on Day 150. Notice that the scab has finally fallen off and the ear shows significant improvement. The patient continued to receive more treatment for the remnant of the keloid behind her ear (not visible in this image).



**Figure 12.** Significant debulking was achieved with one course of cryotherapy. Image on the right shows the healing skin 7 weeks after application of contact cryotherapy. All such patients need ongoing care and management of all their keloid lesions.

### Ear Keloids

The best treatment results with cryotherapy are achieved in patients with ear keloids. With repeated cycles of cryotherapy almost all ear keloids, no matter how small or how large they may be, can be successfully removed.

The purpose of using cryotherapy as the first-line treatment for ear keloids is to avoid the risks associated with surgery and adjuvant radiation therapy [5,6]. As opposed to surgery, that carries a well-known risk for worsening of

the keloid lesions, cryotherapy does not pose such a risk. Indeed, there are no published reports to even indicate such a causal association.

Successful treatment of keloids with cryotherapy requires *patience* and *perseverance*, both from the treating physician as well as the patient. Both parties need to commit to repeated cycles of treatment on a regular basis. Cryotherapy shall be repeated until all protruding components of the keloid are removed.

The two most important factors that determine the length of treatment are the size of the ear keloid and issues related to scheduling the treatment sessions. In fully compliant patients who have either small or large size ear keloids, the whole treatment process may take up to nine months with outstanding results. The course of treatment for patients with semi-massive and massive ear keloids will last longer.

### OTHER METHODS OF CRYOTHERAPY

Other methods of cryotherapy, such as using a spray gun or intra-lesional cryotherapy should be avoided. There is no need to perforate the body of the keloid with a very large-bore metallic cannula and to run liquid nitrogen through the core of the keloid. There exists no data, and no evidence to support the superiority of this invasive technique to standard, non-invasive contact cryotherapy.



## POST-CRYOTHERAPY INFECTION

As the treated tissue loses its integrity, and with breakdown of the skin, the site of cryotherapy is at risk for development of local infection. All patients should be educated about this risk. Early signs of an infection are persistent oozing, new onset pain and new onset erythema in the normal appearing skin that surrounds the treated keloid.

The great majority of patients who undergo cryotherapy will have an uneventful post-procedure course and will not encounter any complications. Having treated over 400 patients with ear keloids and most with multiple ear keloids, the author has encountered only a handful of cases of post-cryotherapy infections. Most of these patients do very well with oral antibiotics such as sulfamethoxazole/trimethoprim (Bactrim) or ciprofloxacin. Two patients, one with a massive

ear keloid, and one with a semi-massive ear keloid needed to receive intravenous antibiotics for a few days (as out-patient) for treatment of locally advanced infections.

## FOLLOW-UP AFTER CRYOTHERAPY

Although we can successfully debulk and remove almost all primary ear keloids with cryotherapy, there is a clear need for follow-up in all patients in order to detect and treat early recurrences.

The goal of cryotherapy in the settings of nodular and tumoral keloids is to achieve total ablation of the keloid tissue. In instances where total ablation is achieved, and the underlying ear tissue/earlobe is totally free of any keloid tissue, the author stops all treatments and advises his patients to simply monitor their ears and report back immediately if they notice any signs of recurrence.

## REFERENCES

1. Allington HV, Liquid nitrogen in the treatment of skin diseases. *Calif Med.* 1950 Mar;72(3):153-5.
2. Muti E, Ponzio E. Cryotherapy in the treatment of keloids. *Ann Plast Surg.* 1983 Sep;11(3):227-32.
3. Rusciani L, Rossi G, Bono. Use of cryotherapy in the treatment of keloids. *R J Dermatol Surg Oncol.* 1993 Jun;19(6):529-34.
4. Package Insert - Exparel®.
5. Miyahara H1, Sato T, Yoshino K. Radiation-induced cancers of the head and neck region. *Acta Otolaryngol Suppl.* 1998;533:60-4.
6. Ron E. Cancer risks from medical radiation. *Health Phys.* 2003 Jul;85(1):47-59.